Microcurrent as an Adjunct Therapy in Accelerating Wound Healing and Reducing Pain in Patients with Chronic Wounds

Harikrishna K.R. Nair, MD FMSWCP, Wound Care Unit, Dept. of Internal Medicine, SCACC Hospital Kuala Lumpur, Malaysia

ABSTRACT

100 patients with chronic wounds were randomly selected to assess the efficacy of microcurrent as an adjunct therapy in reducing wound size, pain score and other parameters for a period of four weeks. Patients enrolled had the following conditions: 64 Diabetic Foot Ulcer; 5 Pressure Injury; 24 Venous Leg Ulcer; 7 other wounds types

The efficacy of microcurrent therapy was assessed according to the reduction in wound area as well as in pain and other inflammatory symptoms which was attributed to its effect on vasodilatation of the vessels and increase in perfusion. Inspection and physical assessment was done with the Visual Analog Scale for pain.

INTRODUCTION

Chronic wounds are regarded as a major problem in terms of social and psychological impact to patients. The mode of action for microcurrent therapy is reducing Inflammation and increasing perfusion. Most chronic wound patients remain in the inflammatory phase of healing with associated pain, which will affect their health-related quality of life (HRQoL) such as sleep, mobility etc.[1]

Studies have shown microcurrent stimulates cellular activity and regeneration by increasing ATP production and repairs tissue by increasing protein synthesis.[4] Microcurrent has been proven to reduce Cortisol and TNF-a levels in terms of pain management,[5] and increase Nitric Oxide, a potent vasodilator which increases perfusion to the wound.[6] Exogenous electrical stimulus has been found to increase growth of blood vessel networks by as much as 50 percent,[7] activating the pathway for angiogenesis and enhancing vascular network growth. As a result, wound closure would be enhanced, leading to faster healing.[8]

METHODOLOGY

100 patients with chronic wounds were enrolled via simple randomized sampling for a period of four weeks. Wound care was performed with Microcurrent Treatment as an adjunctive therapy. In this study, Avazzia BEST™ (Bio-electro Stimulation Technology) devices and accessories were used.

Inclusion criteria:

- All wounds types, including DFU, VU, pressure ulcer, others
- Wound surface area ≥ 0.5 cm2 and ≤ 22 cm2
- Able to comply with weekly clinic visits
- Able to perform daily, at-home microcurrent therapy

Exclusion criteria:

- Use of any microcurrent device w/in 6 mos. prior to study
- Malignancies undergoing treatment or any malignancies
- Low blood pressure
- Electrical implant such as pacemaker or neural stimulator involving musculoskeletal system

Each patient had microcurrent therapy delivered while having their wounds cleansed. Patients were loaned an at-home, microcurrent device to treat themselves 2 to 3 times a day for a period of four weeks. This therapy was applied around the bandaged area (thus not having to open the wound dressing to deliver treatment).

Primary objectives of the treatments:

- reduction in wound area
- reduction in pain

Secondary objectives of the treatments:

- reduction in inflammatory symptoms
- improvement in sleep quality
- increased vasodilation
- improvement in gait
- frequency of bowel movement

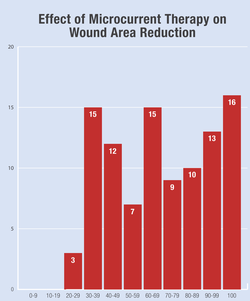

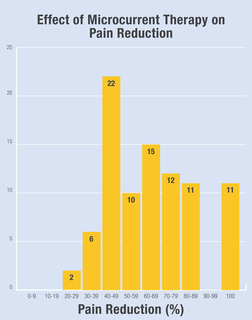

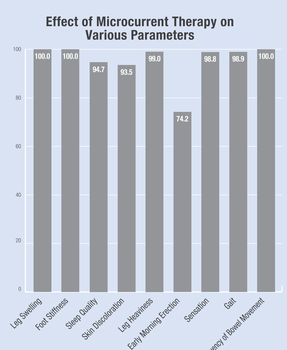

STATISTICAL ANALYSIS

Primary objectives were analyzed using SPSS version 20, using paired t-test method.

CONCLUSION

All 100 subjects had reduction in wound size. Reduction in pain resulted in improved sleep quality. Patients had a likely increase in perfusion, as well as skin coloration, early morning erection and sensation due to the effect of vasodilation of the vessels. There were reductions in inflammatory systems, such as leg swelling and foot stiffness, as well as other parameters such as gait, sensation, and sleeping quality among others. There were no adverse events reported.

RESULTS

A 66 year old Indian gentleman presented with Right Diabetic Foot Ulcer at the 2nd toe for more than 4 months. After 1 month of Microcurrent treatment, wound area reduced by 95%. Neuropathy pain reduced by 75% resulting in improved sleep quality. Foot stiffness and swelling reduced as well as requirement of Tramadol which reduced from 50mg OD to nil. Foot discolouration improved due to improved sensation. This led to improved gait. Patient also noticed improvement in bowel movement in terms of frequency as he previously experienced poor bowel output predominantly.

A 66 year old Chinese gentleman presented with Venous Ulcer on Left Lower Limb for more than 5 years. After 1 month of Microcurrent treatment, the wound healed with full epithelialization. Leg pain reduced by 80%. Leg stiffness and swelling reduced causing improvement in gait. Requirement of Tramadol 50mg BD was reduced to nil. Improvement in leg colour as well as improvement in early morning erection and frequency of bowel movement were noted.

A 58 year old Indian gentleman presented with 3rd stage sacral sore for more than 5 months. After 1 month of Microcurrent treatment, the wound healed with 88% epithelialization. There was 67% reduction in leg pain. There was reduction in leg stiffness causing improvement in gait. In addition there was improvement in the quality of sleep.

A 66 year old Malay gentleman presented with a Right Diabetic Foot Ulcer with Ray's Amputation done in 2015. After 1 month of Microcurrent treatment, there was 100% epithelialization. Neuropathy pain reduced by 83% resulting in requirement of Tramadol 50mg BD reduced to nil and improved sleep. Patient's gait improved due to reduction in foot stiffness, numbness and ankle swelling. Foot colour and sensation improved. Patient experienced improvement in early morning erection and frequency of bowel movement.

A 54 year old Malay gentleman presented with a Left Diabetic Foot Ulcer at the lateral plantar aspect for the past 1 year. Within 1 month of treatment, the wound area reduced 98%. Neuropathy pain reduced by 75% resulting in patient having improved sleep. Foot stiffness and ankle swelling also reduced. He used to require wheelchair assistance but after treatment he could walk without aid. There was noticeable improvement in leg discolouration due to reduction in scar tissues and hyperpigmentation. Patient experienced early morning erection and more frequent bowel movement.

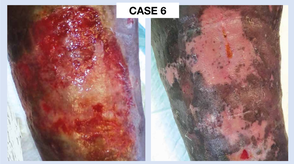

A 62 year old Malay gentleman presented with Venous Ulcer on Right Lower Limb for more than 5 months. After 1 month of Microcurrent treatment, the wound healed with 100% epithelialization. Although pain reduced by 88% and sleep quality improved, patient maintained his pain medication intake OD. Leg stiffness and swelling reduced causing improvement in gait. Improvement in leg discolouration as well as improvement in early morning erection and frequency of bowel movement were noted.

References

1. Faria E, Blanes L, Hochman B, et al. Health-related Quality of Life, Self-esteem, and Functional Status of Patients With Leg Ulcers.
2. Upton D, Solowiej K. Pain and stress as contributors to delayed wound healing
3. Mayer E. The neurobiology of stress and gastrointestinal disease. http://gut.bmj.com/content/47/6/861.full.pdf+html
4. Cheng N, Van Hoff H, Bockx E, et al. The Effects of Electric Currents on ATP Generation, Protein Synthesis, and Membrane Transport in Rat Skin.
5. Ng MM, Avazzia Biofeedback Electrostimulation Therapy (Avazzia BEST): Its Effect On Changes in Pain Biomarkers on Chronic Neuropathic Pain: A Prospective Randomised Controlled Trial
6. Lee ZS, BEST (Biofeedback Electro-Stimulation Therapy) on Chronic Neuropathic Pain: Effects on Pain Score and Pain Biomarker Nitric Oxide
7. M.B. Reilly. UC Research Tests Range of Electrical Frequencies that Help Heal Chronic Wounds. http://www.uc.edu/news/NR.aspx?id=19331.
8. Harikrishna K.R. Nair, Compendium of Wound Care Dressings in Malaysia, 3rd Edition

Data presented has not been reviewed or evaluated by the US FDA. Devices are not intended for the diagnosis or treatment of disease condition. Avazzia devices are US FDA cleared as TENS for symptomatic relief and management of chronic, intractable pain, and adjunctive treatment in the management of post-surgical and post-traumatic pain. This study is for Microcurrent as an adjunct therapy in accelerating wound healing and reducing pain in patients with chronic wounds. Avazzia microcurrent devices are US FDA cleared for pain relief.

Assessing Perfusion with Vascular Angiography Following Neuromodulation Treatment For Chronic Wound

Following the 100-patient study, Dr. Nair conducted an exploratory trial of five (5) patients to assess perfusion with neuromodulation treatment using varied techniques. Perfusion of the treated area was assessed with vascular angiography (LUNA System, manufactured by NOVADAQ). Techniques included direct or indirect epidural contact (around the wound) using the neuromodulation device's built-in stainless steel electrodes; self-adhesive electrode pads or a hand-held Y-electrode accessory.

All patients experienced an immediate increase in perfusion in the treated area. The average increase in perfusion was between 20% and 264%, depending on the technique utilized.

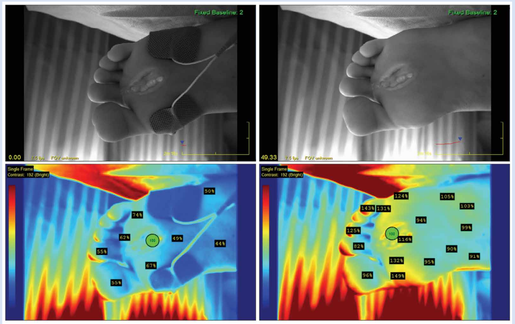

Left: perfusion pre-neuromodulation treatment. **Right:** perfusion post-neuromodulation treatment with self-adhesive electrode pads. An increase in perfusion of 264% was observed. The increase in yellow to red colorization indicates improved perfusion.

Evaluating Bio-electro Neuromodulation in the Wound Care Clinic

Medical centers in the United States are currently collaborating to evaluate a bio-electro neuromodulation device (FDA-cleared for pain relief) and assess its potential to increase perfusion in chronic wounds. The simplicity of the unique, damped sinusoidal wave technology combined with intelligent feedback to the body's responses, provide clinicians with a convenient, hand-held, battery-powered treatment for easy use within the wound care clinic.

Bio-electro Stimulation Technology (B.E.S.T.) can be applied with direct or indirect epidermal contact using any of the following techniques:

- Built-in stainless steel electrodes
- Adhesive electrode pads
- Y-electrode

RA-CSR-161003-02